# POST-TRAUMATIC HEADACHE ASSESSMENT

NATHAN D. ZASLER, MD
CEO & MEDICAL DIRECTOR,
CONCUSSION CARE CENTRE OF VIRGINIA
AND TREE OF LIFE SERVICES
AFFILIATE PROFESSOR, PM&R, VCU
ASSOCIATE PROFESSOR, PM&R, UVA
VICE-CHAIRPERSON, IBIA

DVBIC Grand Rounds, 9/22/14

# INTRODUCTION

- Post-traumatic headache (PTHA) or cephalalgia is often diagnosed after closed head injury and traumatic brain injury (TBI) but remains poorly understood on multiple levels.
- The assessment methodologies for PTHA have not been well studied.
- The history and physical exam are two critical pieces of any clinician’s assessment that serves to guide a correct diagnosis, as well as correct treatment.

# PTHA SYMPTOM OVERLAP

- Using only the International Headache Society Classification can lead to false positive headache diagnoses.
- Aching, throbbing pain can be seen with migraine, tension-type headache (TTHA), temporomandibular joint disorder (TMJD), site of impact injuries and referred cervicogenic pain.
- Autonomic concomitants can be seen with migraine, TTHA, and certain referred headache pains.

# PTHA SYMPTOM OVERLAP

- Unilateral versus bilateral headache can be seen with numerous different PTHA disorders
- Laterality or absence thereof is not pathognomonic for any particular PTHA phenotype.

# SYMPTOMS POTENTIALLY ASSOCIATED WITH PTHA

- Irritability
- Depression
- Anxiety
- Cognitive impairment
- Phonosensitivity
- Photosensitivity
- Tinnitus
- Insomnia
- Blurred vision
- Nausea but rarefy emesis
- Aura (migraine specific)

# CLINICAL CAVEATS

- Clinicians should not only rely on classification systems but more importantly on PTHA history, physical exam and a knowledge of the known PTHA pain generators.
- The first goal should be to use good differential diagnosis to identify the most likely PTHA pain generators.
- Don’t stop after just the first one as there are often more than one cause.

# ASSESSMENT CHALLENGES

- There are no standardized or evidence based exam protocols for any sub-type of PTHA.
- There is a high degree of examiner variability in how long is spent in PTHA evaluation, what historical information is garnered and how thoroughly the patient is actually examined.

# HISTORY OF PTHA

- Pre-injury headache history
- Family headache history
- Temporal relationship of headache with injury
- Evolution of headache symptoms over time
- Prior treatment for headache
- Treatment response history

# HISTORY OF PTHA

- “Colder” mnemonic
- Severity and frequency
- Time of day
- Prodromal symptoms
- Triggers
- Associated headache symptoms
- Functional consequences
- Dietary, lifestyle, hormonal and/or genetic influences?

U.S. Army Photo by Pfc. Paige Pendleton

# EXAMINATION

- INSPECTION:
  - Body asymmetries including shoulder droop, pelvic asymmetry, hemiatrophy, leg length discrepancy (may be functional), and hemi-gait.
  - Posture including head forward posture, loss of cervical lordosis, rounded shoulders, kyphosis, dystonic posturing, spastic posturing.
  - Range of motion assessment - jaw range of motion (ROM), cervical spinal ROM.

http://en.memory-alpha.org/wiki/Vulcan_mind_meld

# EXAMINATION

- Auscultation:
  - TMJ as indicated
  - Bruit check – 4 sites – as indicated
- Palpation:
  - Shoulder girdle, neck, face (masticatory muscles) and head including TMJ
  - Assess muscle turgor, soft tissue irritability, vertebral somatic dysfunction, trigger vs. tender points, sensory changes (allodynia, dysesthetic, etc.), + Tinel's

# EXAMINATION

- Screening neurological exam
- Response bias assessment
- Psychoemotional evaluation
  - Adjustment disorder
  - Depression
  - Anxiety
  - PTSD
  - Stress tolerance and coping

# MAJOR PTHA SUBTYPES

- Cervicogenic
- Musculoskeletal
- Myofascial
- TMJD
- Neuritic and neuralgic
- Migraine
- Tension
- Medication overuse headache (MOH)
- Medication induced headache (MIH)

# WHAT NOT TO FORGET

- There are unusual and uncommon causes of PTHA – know them!
- Not all PTHA is in fact post-traumatic – keep in mind other non-traumatic headache disorders, temporal onset may lead to misattribution:
- Pre-existing headache disorders (may be exacerbated or aggravated) by trauma
- Substance abuse
- Sinus disease
- Temporal arteritis
- Space occupying lesions
- Caffeine withdrawal

# UNCOMMON CAUSES OF PTHA

- Cluster headache
- Paroxysmal hemicrania
- Late or slow extra-axial bleeds
- Post-traumatic epilepsy
- Intracranial pressure abnormalities
- Tension pneumocephalus
- Carotid cavernous fistula
- Post-traumatic sinus headache

# CERVICOGENIC HEADACHE

- Cervicogenic headaches may be related to dysfunction of the facet joints (Bogduk, 2005).
- Others have hypothesized that chronic pain following cervical acceleration-deceleration type injuries may be due to central sensitization (Curatolo, Arendt-Nielsen, Petersen-Felix, 2004).

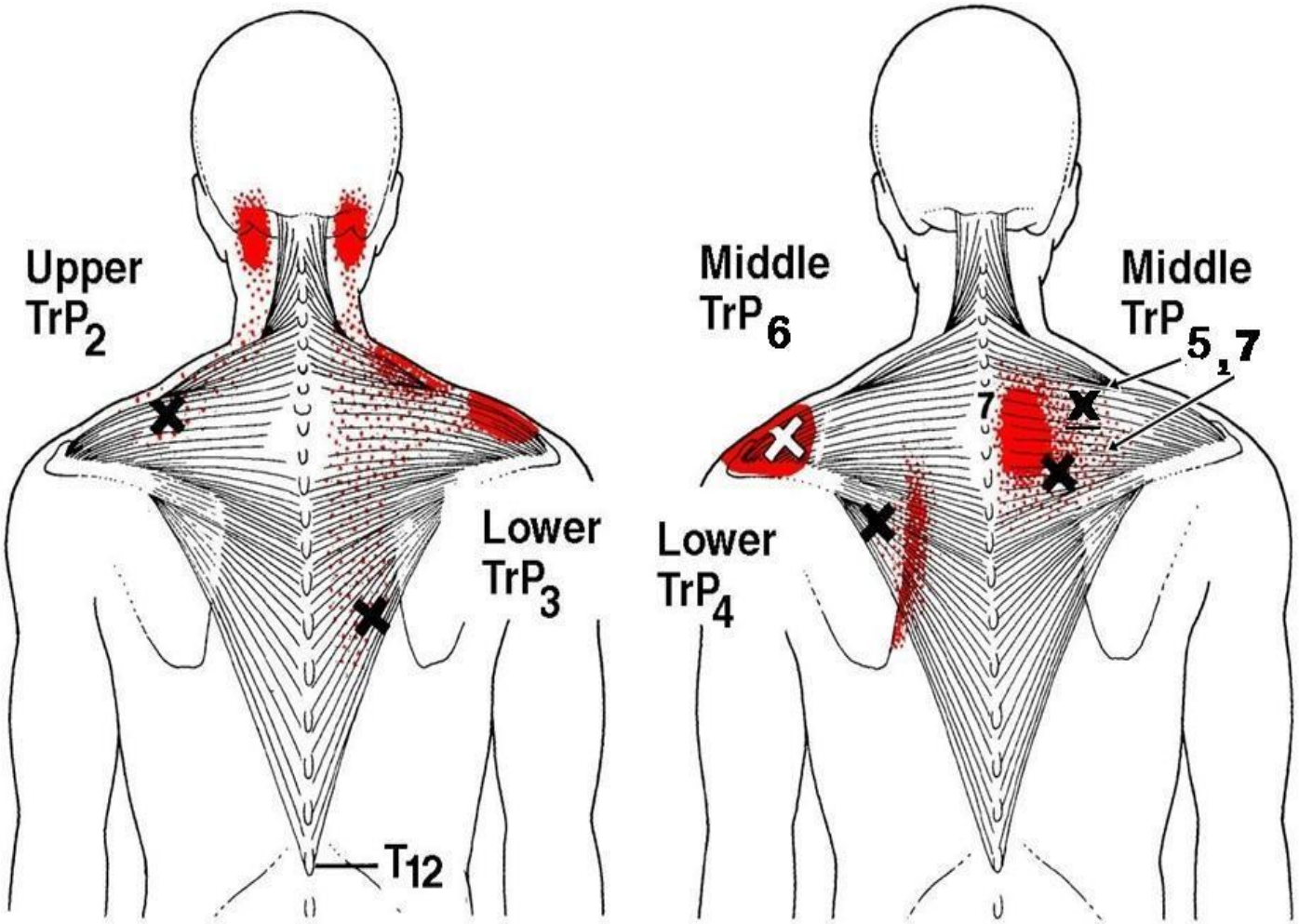


Used with permission by: http://www.freebodied.com/tag/trigger-point-therapy-salt-lake-city/

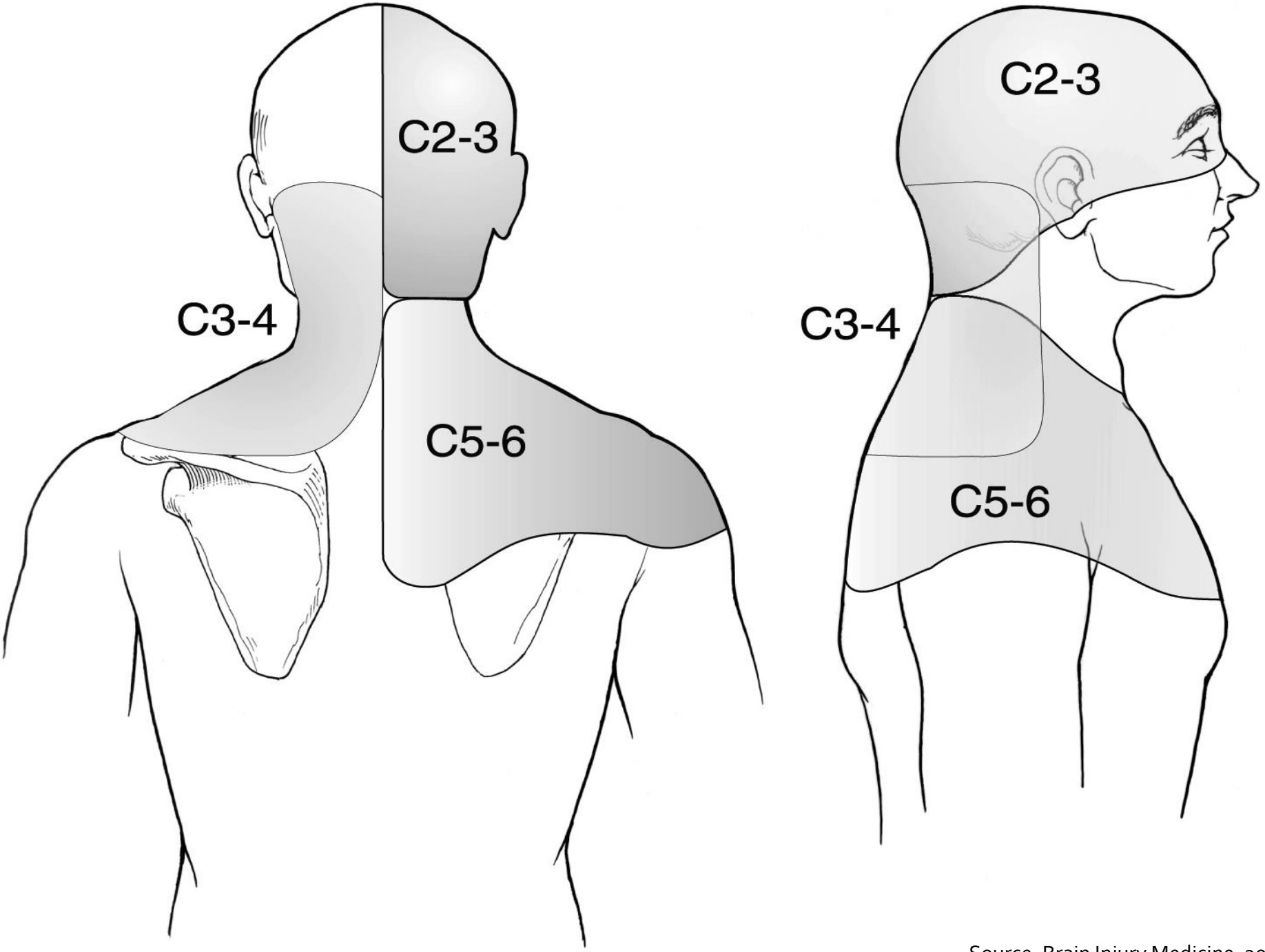


Source: Brain Injury Medicine, 2013

# CERVICOGENIC HEADACHE

- Cervicogenic headache is quite common following trauma.
- Some have argued that it is likely the most common etiology of post-traumatic headache.
- Numerous treatments have been assessed, most with sub-optimal study methodologies.

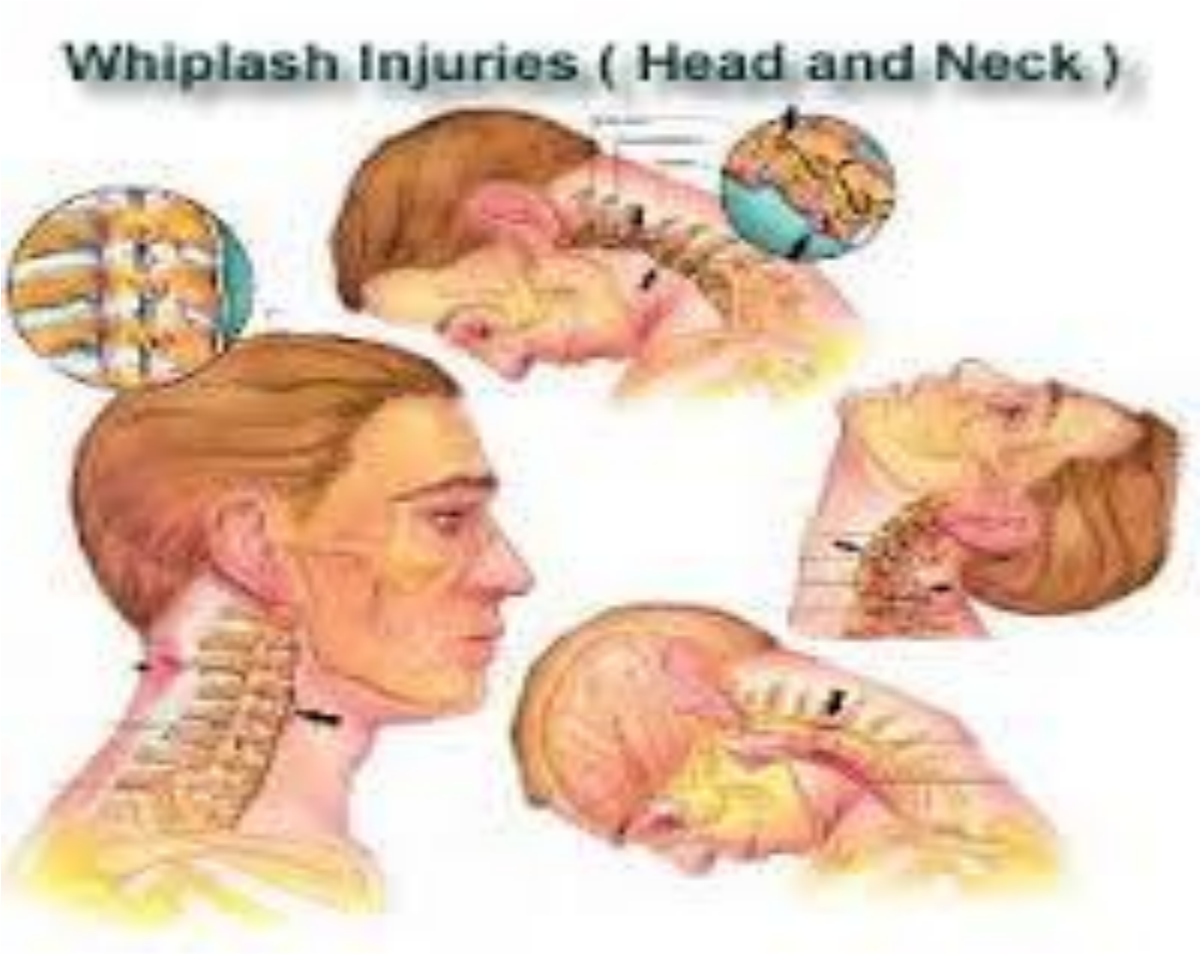


Used with permission from: [http://alliancerehab.info/conditions-we-treat/whiplash.html](http://alliancerehab.info/conditions-we-treat/whiplash.html)

# CERVICOGENIC HEADACHE

- Most patients present with unilateral (albeit sometimes bilateral) sub-occipital pain as well as secondary oculo-frontotemporal discomfort/pain
- Dysfunction of the cervical zygapophyseal joints, particularLy at C2 and C3 may refer pain into the head.

# CERVICOGENIC HEADACHE

- Controversial issues:
  - Ligamentous referred pain (e.g. transverse ligament of the atlas)
  - Cervical instability as a cause of pain and headache
  - Methods for assessing instability
  - What defines clinically significant instability?

# CERVICAL INSTABILITY

- Cervical instability is commonly associated with the upper cervical spine.
- The alar and transverse ligaments provide the primary source of stability for the upper spine.

# CERVICAL INSTABILITY

- Up to 3 mm of displacement of the atlas on the axis implies that the transverse ligament is likely intact, while ligament laxity and even rupture are implied if displacement is from 3–5 mm.
- When displacement exceeds 5 mm, it may be assumed that the ligament has ruptured and the accessory ligaments are stretched and partially deficient.

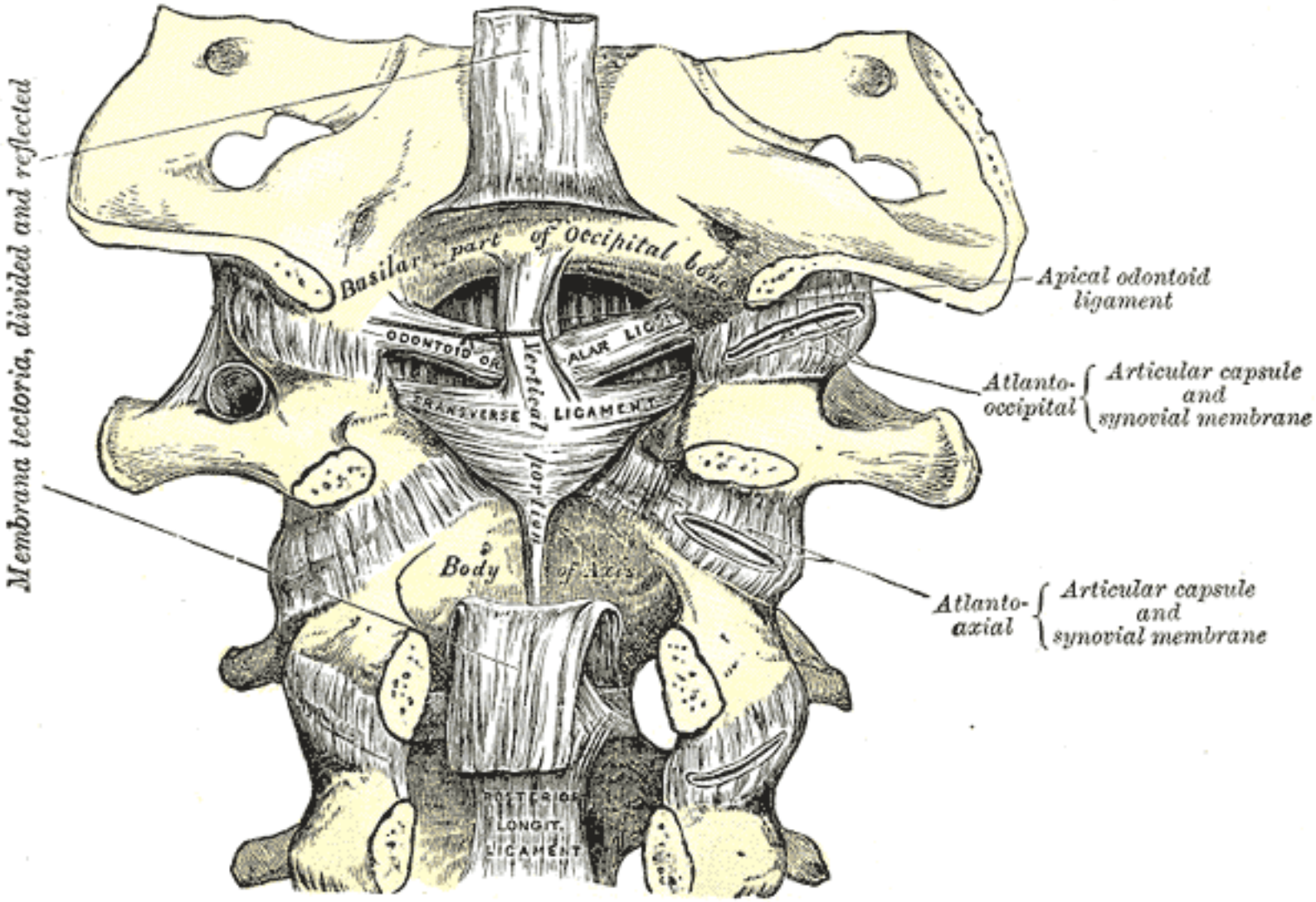


Source: http://en.wikipedia.org/wiki/Tectorial_membrane_of_atlanto-axial_joint#mediaviewer/File:Gray307.png

# UPPER CERVICAL STABILITY

- The alar ligaments connect the cranium to C1 from the sides of the dens to the lateral borders of the foramen magnum
- The alar ligaments function to prevent excessive rotation at the atlanto-occipital joint and is most commonly injured in MVA's.
- Less likely to lead to neuro-vascular injury.

# UPPER CERVICAL STABILITY

- The transverse ligament is located across the arch of the atlas and positions the dens against the anterior arch of the atlas.
- Limits flexion and provides support from anterior translation of C1.
- If the transverse ligament is disrupted by injury, neural or vascular compromise could occur due to the proximity of the cord and vertebral arteries.

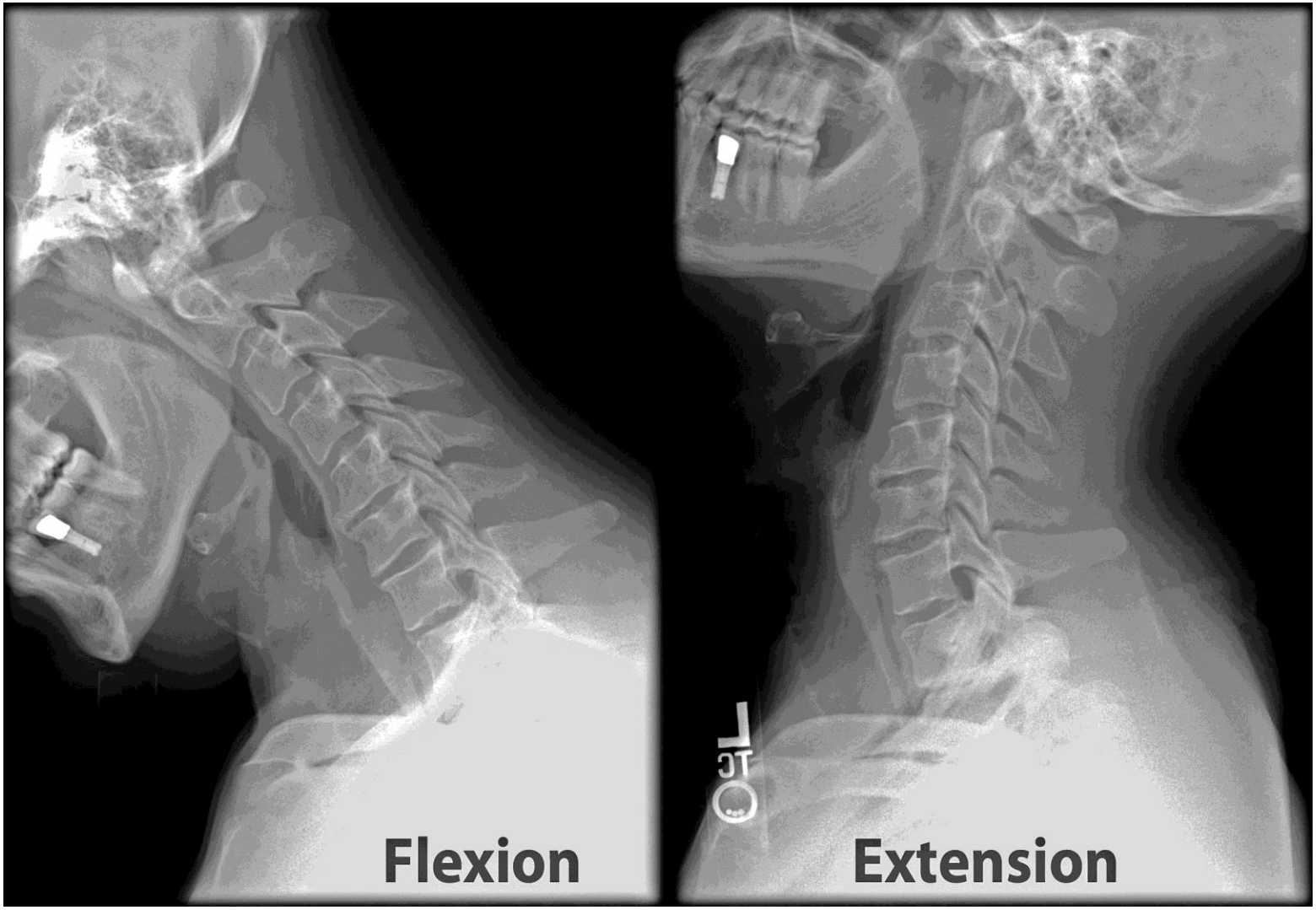


http://commons.wikimedia.org/wiki/File:Cervical_XRayFlexionExtension.jpg

# CLINICAL BEDSIDE TESTING FOR UPPER CERVICAL INSTABILITY

- Sharp-Purser test - + test if decrease in symptoms and/or clunk and no sliding with posterior to anterior movement
- Alar ligament stress test - + test if with passive movement there is a lag or delay of C2 spinous process movement
- Anterior shear test or transverse ligament test - + test if there is a sensation of lump in the throat or the presence of cardinal signs

# Sharp-Purser Test

Photo Source: Physiopedia.com

# Alar ligament stress test

Photo Source: Physiopedia.com

Anterior shear test or transverse ligament test

Photo Source: Physiopedia.com

# LOWER CERVICAL SPINE

- In contrast to the upper cervical spine, the frontal plane orientation of facet joints of the lower cervical spine serves as the primary source of stability.
- Spinal segments contributing to lower cervical spinal syndrome (LCSS) include ligamentum nuchae, anterior longitudinal ligament, posterior longitudinal ligament and the ligamentum flavum.

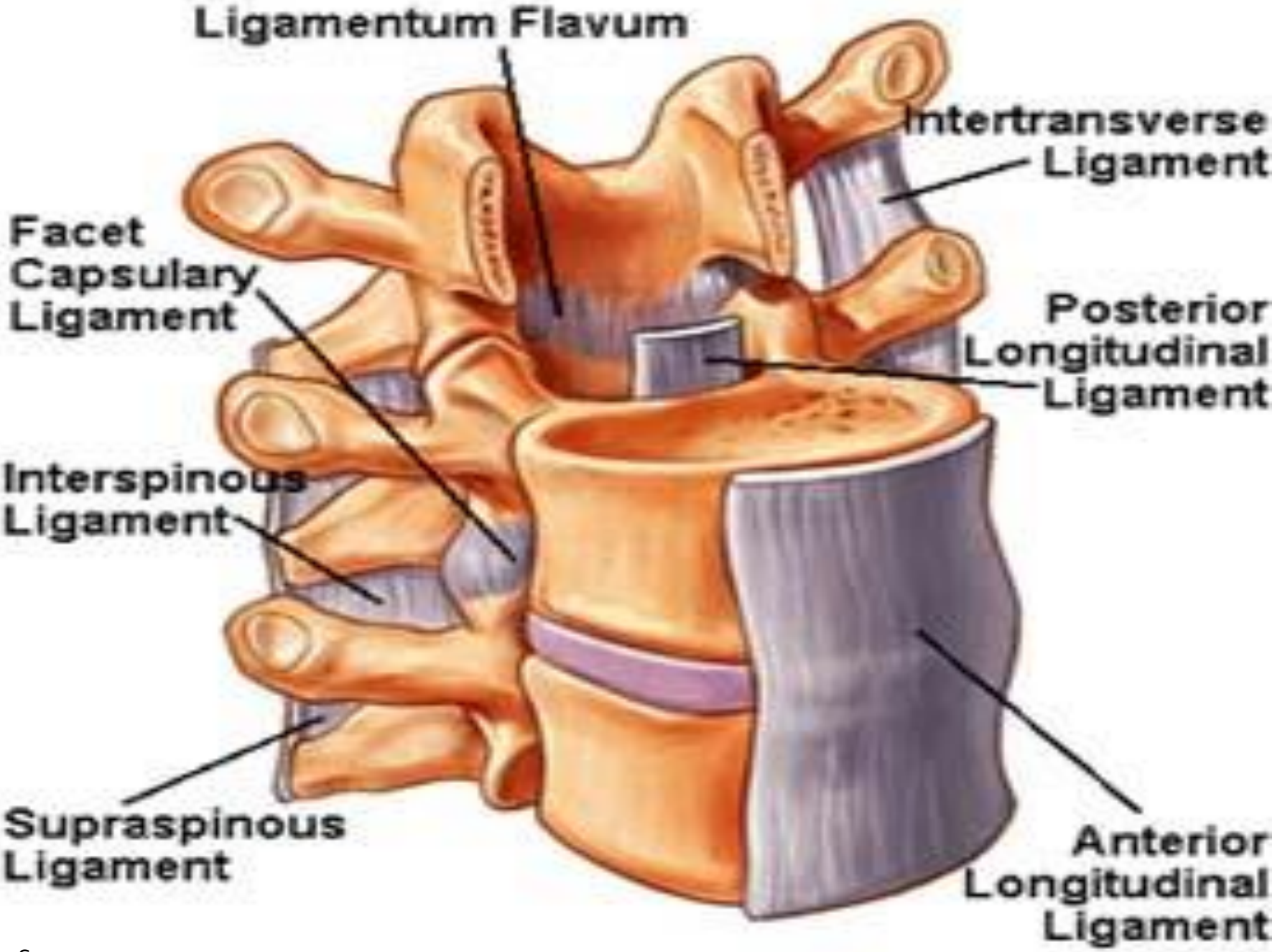


Photo Source: emoryasp.com

# MUSCULOSKELETAL HEADACHE (HA)

- Dull aching type pain
- Tends to be constant
- Typically improves with time
- Activity and barometric pressure changes may exacerbate the headache

Dr. Janet Travell & Dr. David G Simons 1977
Photo courtesty of Dr. David G. Simons

http://koushikphysio.blogspot.com/2010/11/myofascial-pain-syndrome-and-trigger.html

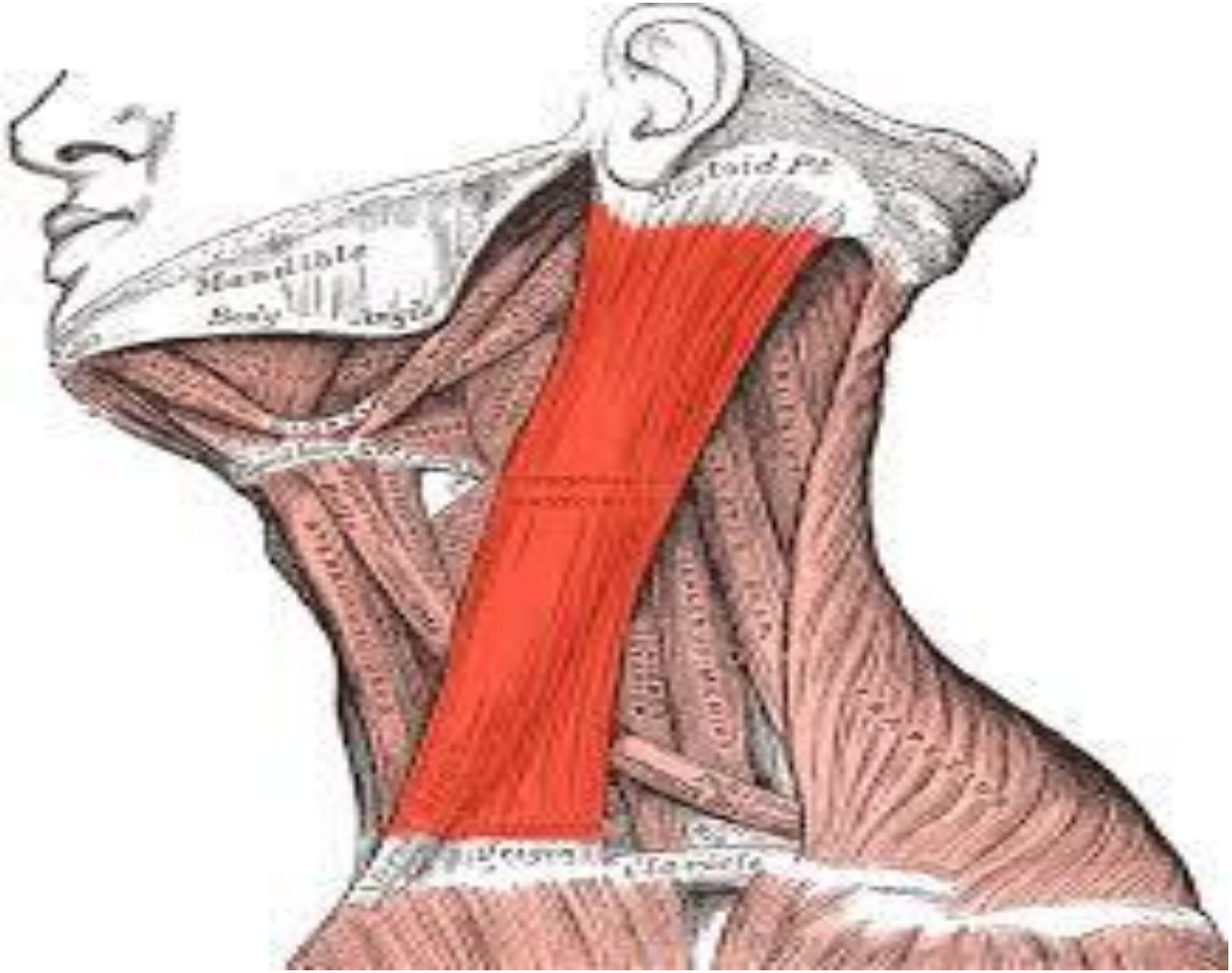


Source: http://en.wikipedia.org/wiki/Sternocleidomastoid_muscle

# MYOFASCIAL HA

- Most common PTHA variant
- Pressure/tension
- Worse with stooping bending and exertion
- May be associated with dizziness and photosensitivity
- Referred pain patterns critical to understand

# CONVERGENCE PROJECTION THEORY (CPT) AND MYOFASCIAL PAIN

- Patients may present with unusual symptoms associated with myofascial pain dysfunction zone of referred pain that CPT can explain.
- Myofascial pain is very common in the sternocleidomastoid (SCM) and trapezius after whiplash or inertial injury.
- Zone of referred pain for the SCM extends to retro- and peri-orbital areas.

# CONVERGENCE PROJECTION THEORY AND MYOFASCIAL PAIN

- Overlap exists in the sensory dermatomes for the SCM and the trigeminal tract.
- The second order neurons from CN VII, IX and X are located nearby in the nucleus caudalis of V.
- The zone of referred pain to the ear overlaps with the vagus sensory area.

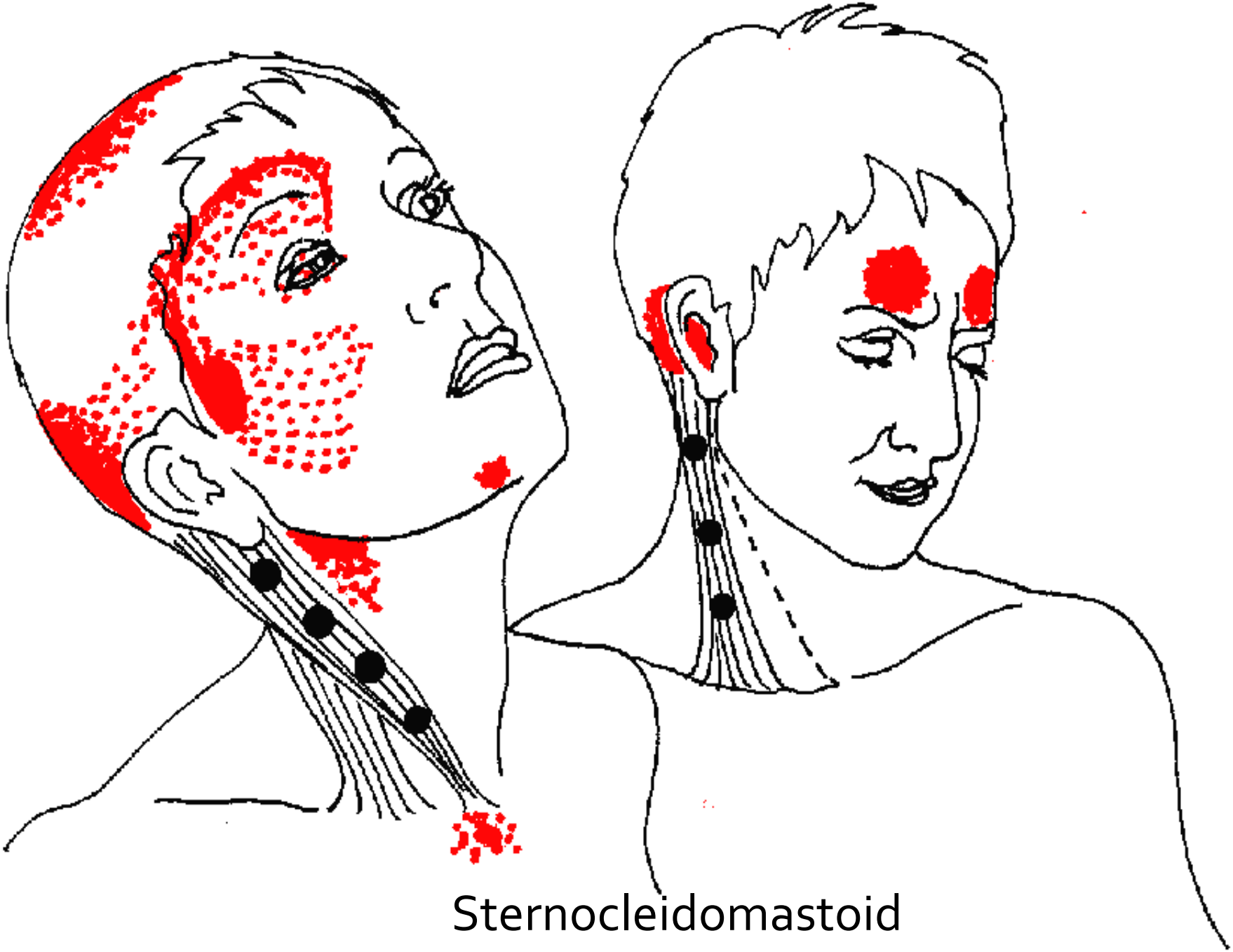

Sternocleidomastoid

Sourhttp://round-earth.com/HeadPainIntro.html with permission to use by C.M. Shifflett

# Trapezius

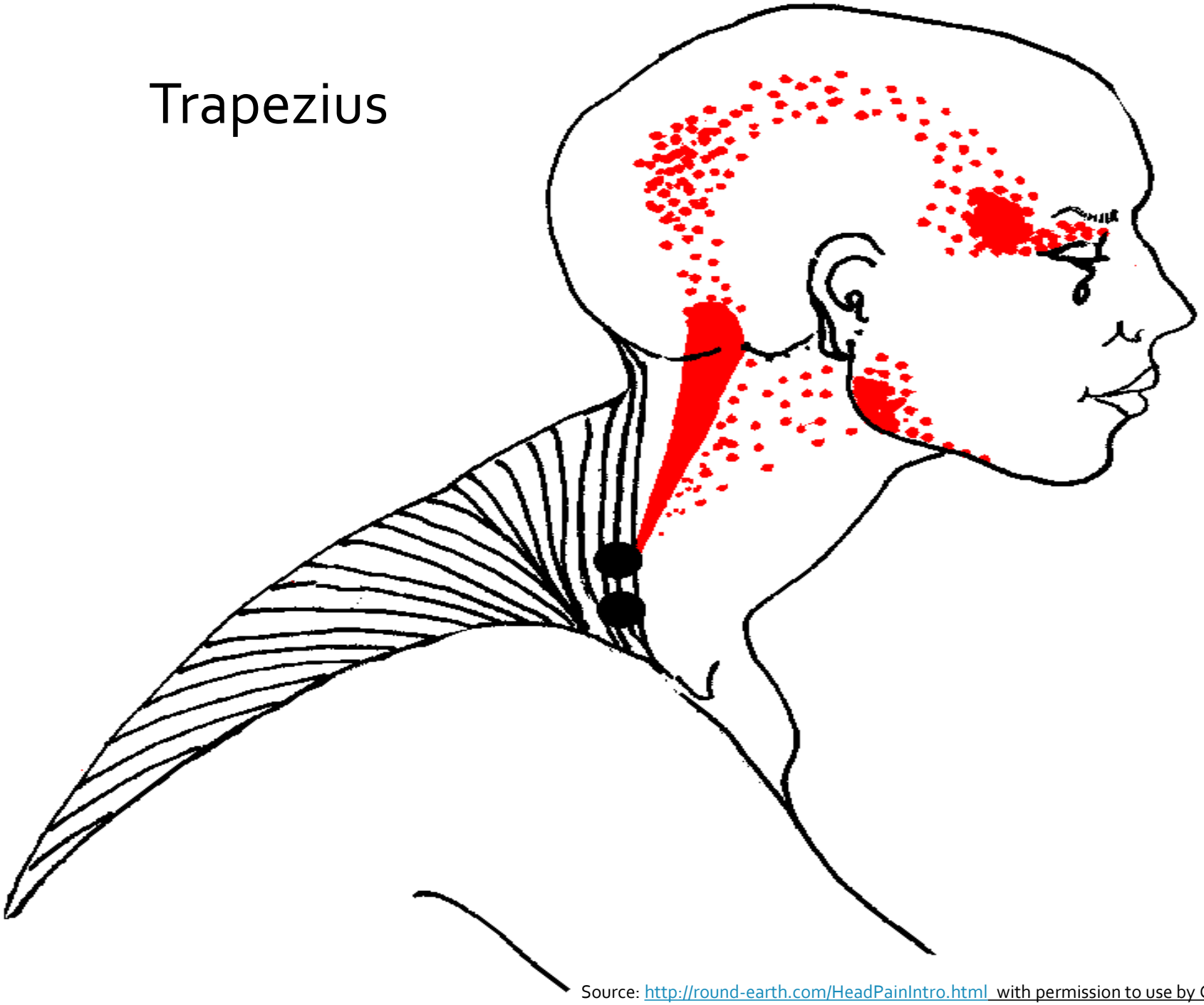

Source: http://round-earth.com/HeadPainIntro.html with permission to use by C.M. Shifflett

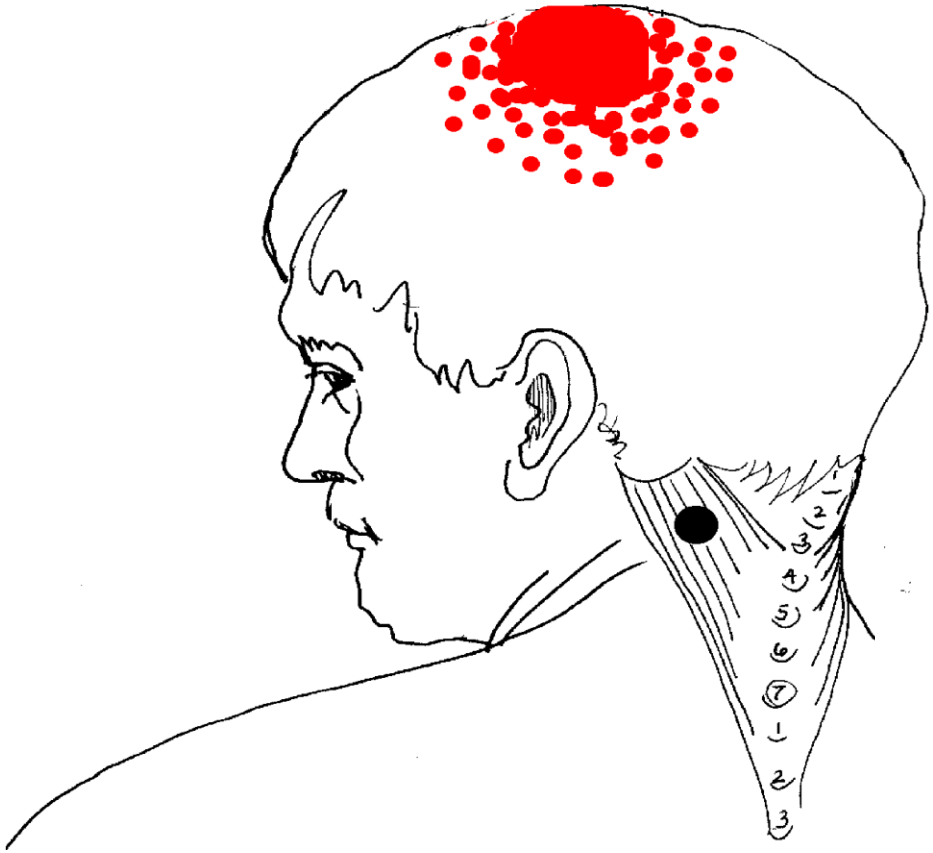

# Splenius cervicis

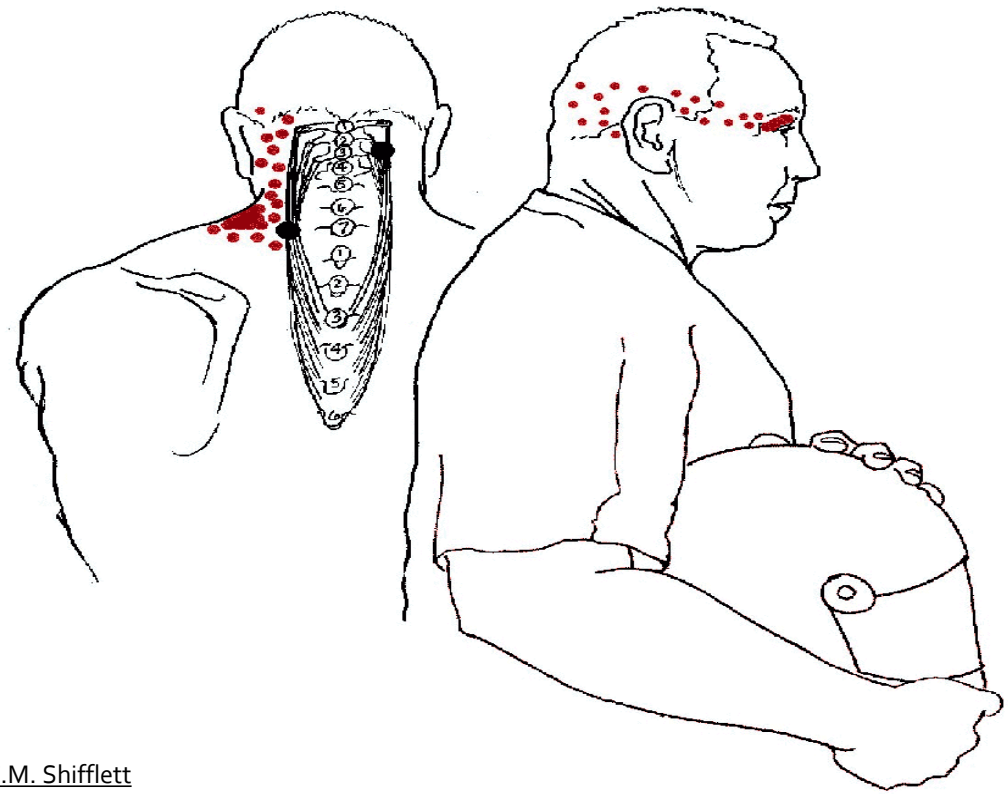

Source: http://round-earth.com/HeadPainIntro.html with permission to use by C.M. Shifflett

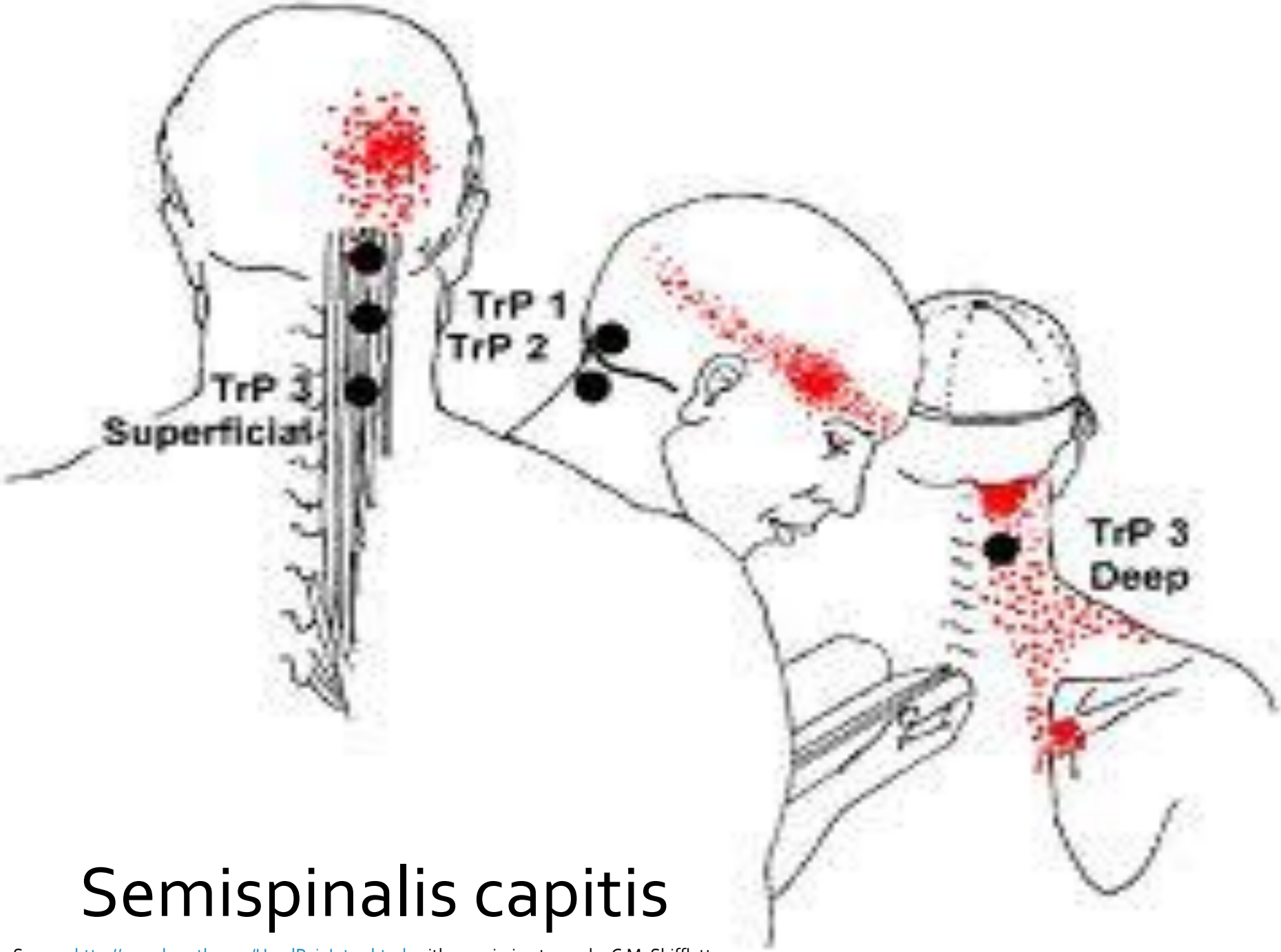


# Semispinalis capitis

Source: http://round-earth.com/HeadPainIntro.html with permission to use by C.M. Shifflett

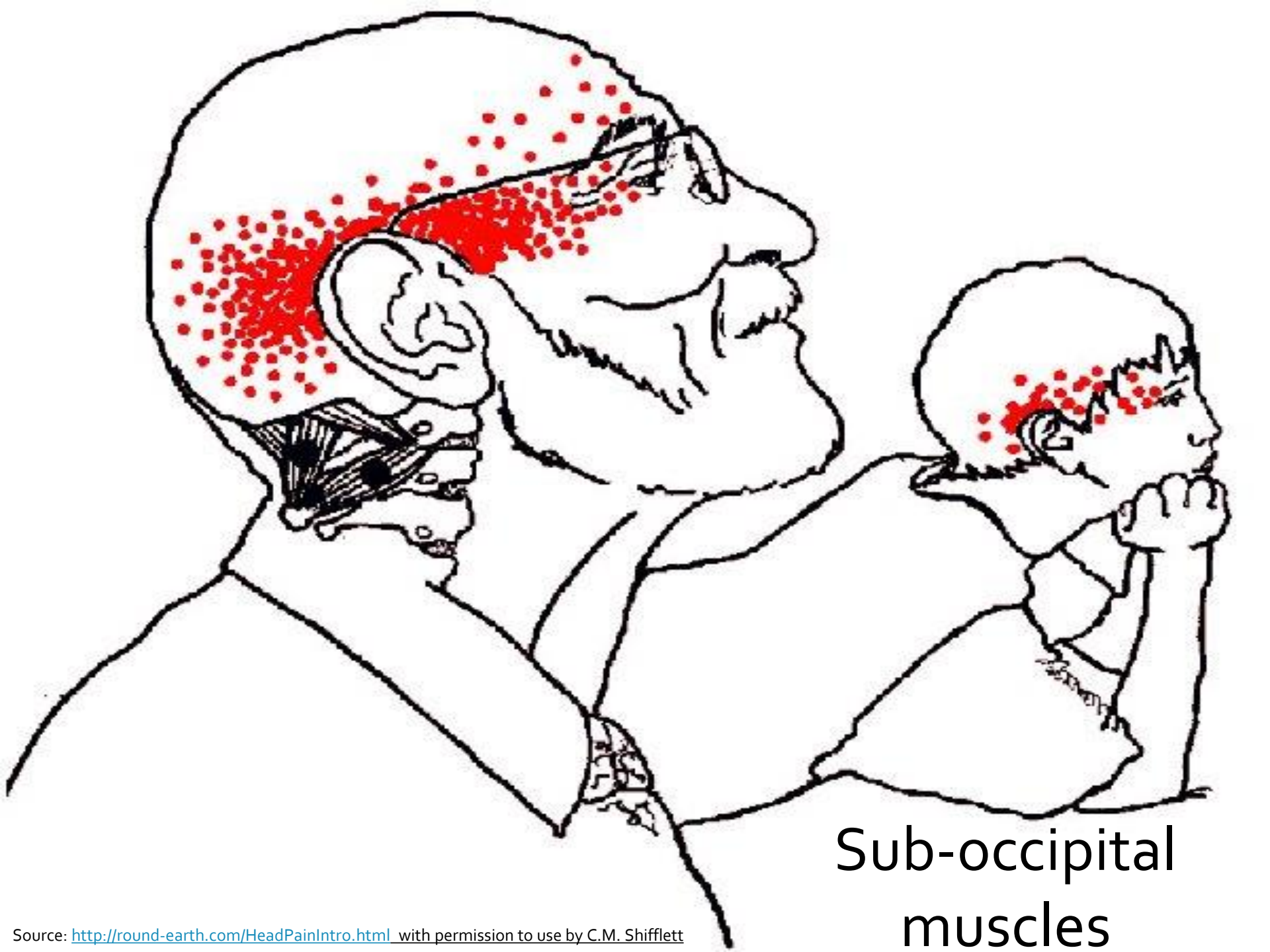


Source: http://round-earth.com/HeadPainIntro.html with permission to use by C.M. Shifflett

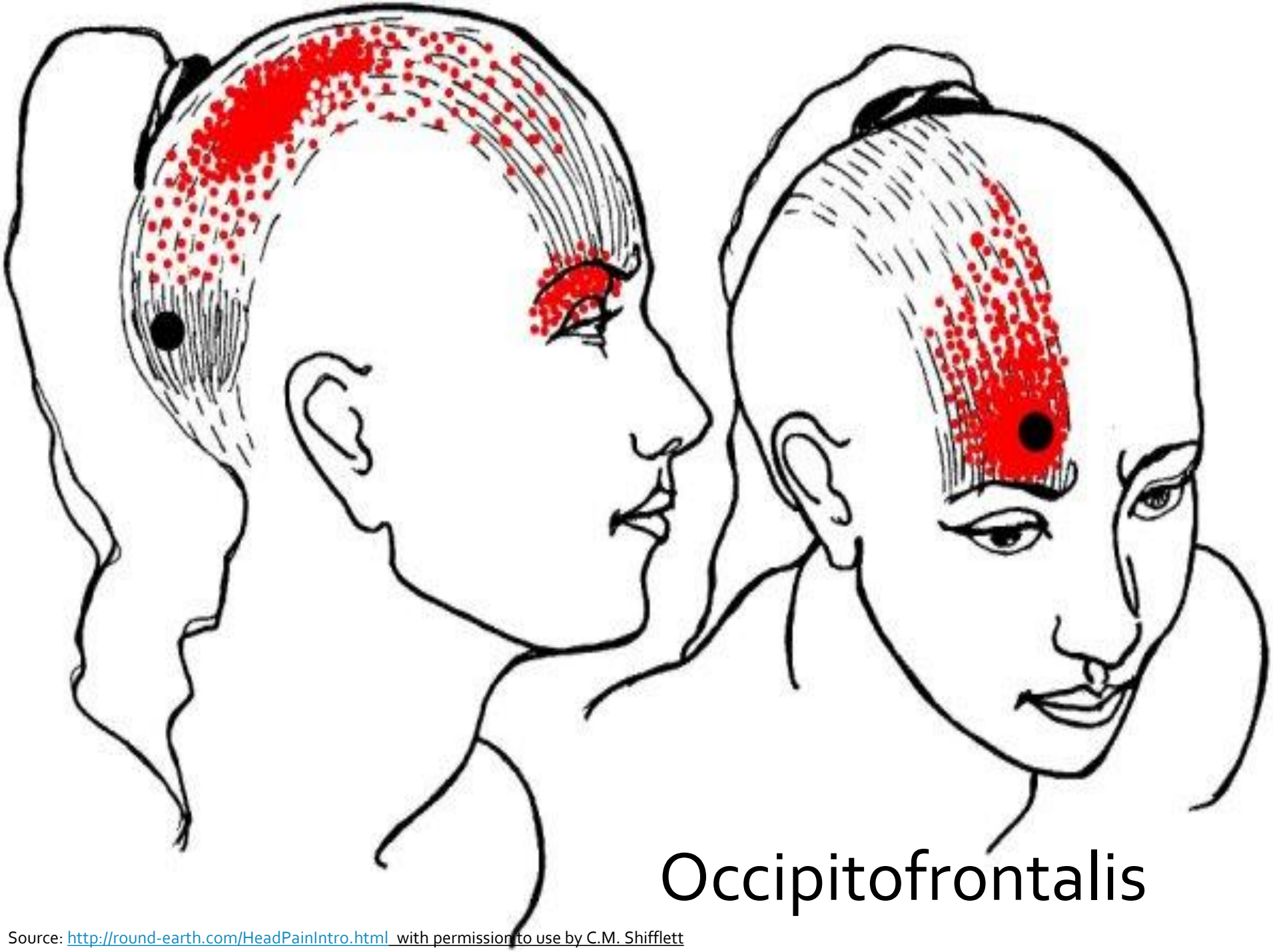


Source: http://round-earth.com/HeadPainIntro.html with permission to use by C.M. Shifflett

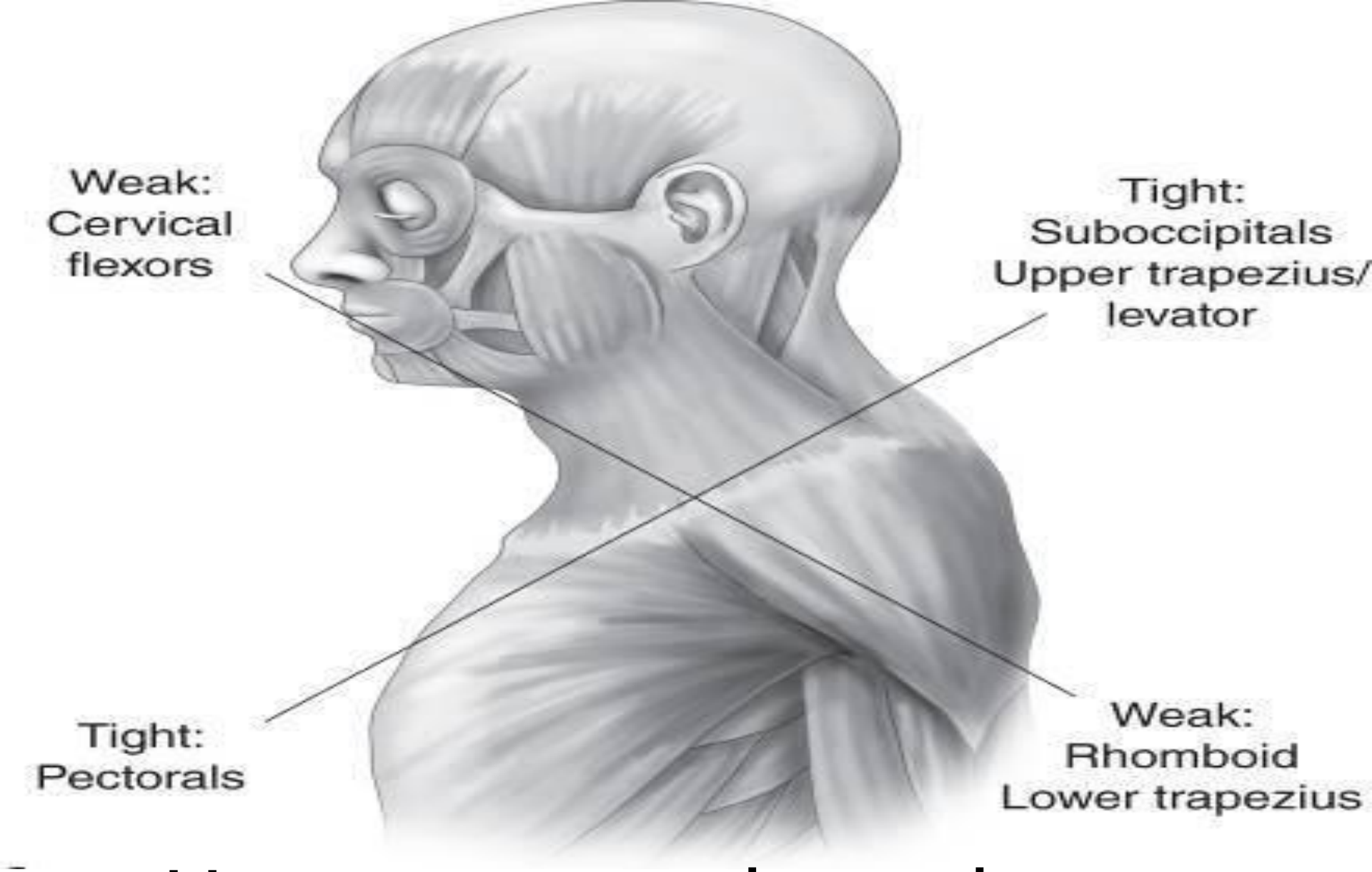


# Upper crossed syndrome

Reprinted, by permission, from P. Page, C.C. Frank, and R. Lardner, 2010, Assessment and treatment of muscle imbalance: The Janda approach (Champaign, IL: Human Kinetics), 52.

# TEMPOROMANDIBULAR DISORDER (TMJD)

- Headache symptoms associated with post-traumatic TMJ
  - Localized ache
- MPD > Intra-articular injury
- Jaw ROM test

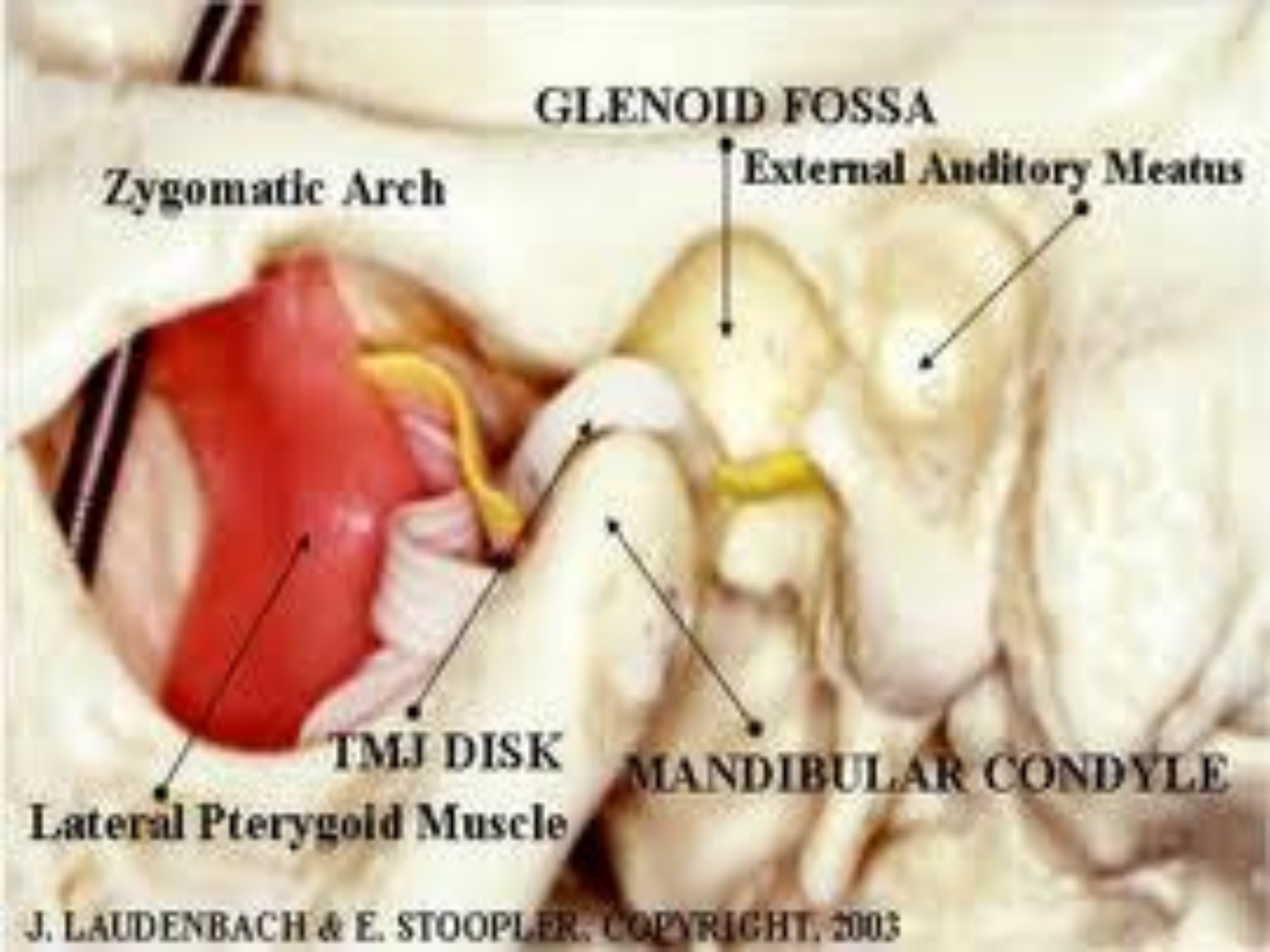
GLENOID FOSSA
External Auditory Meatus
Zygomatic Arch
TMJ DISK
MANDIBULAR CONDYLE
Lateral Pterygoid Muscle
J. LAUDENBACH & E. STOOPLER. COPYRIGHT. 2003

Source: http://www.whiplashandtmj.com with permission to use by Dr. Dennis Steigerwald

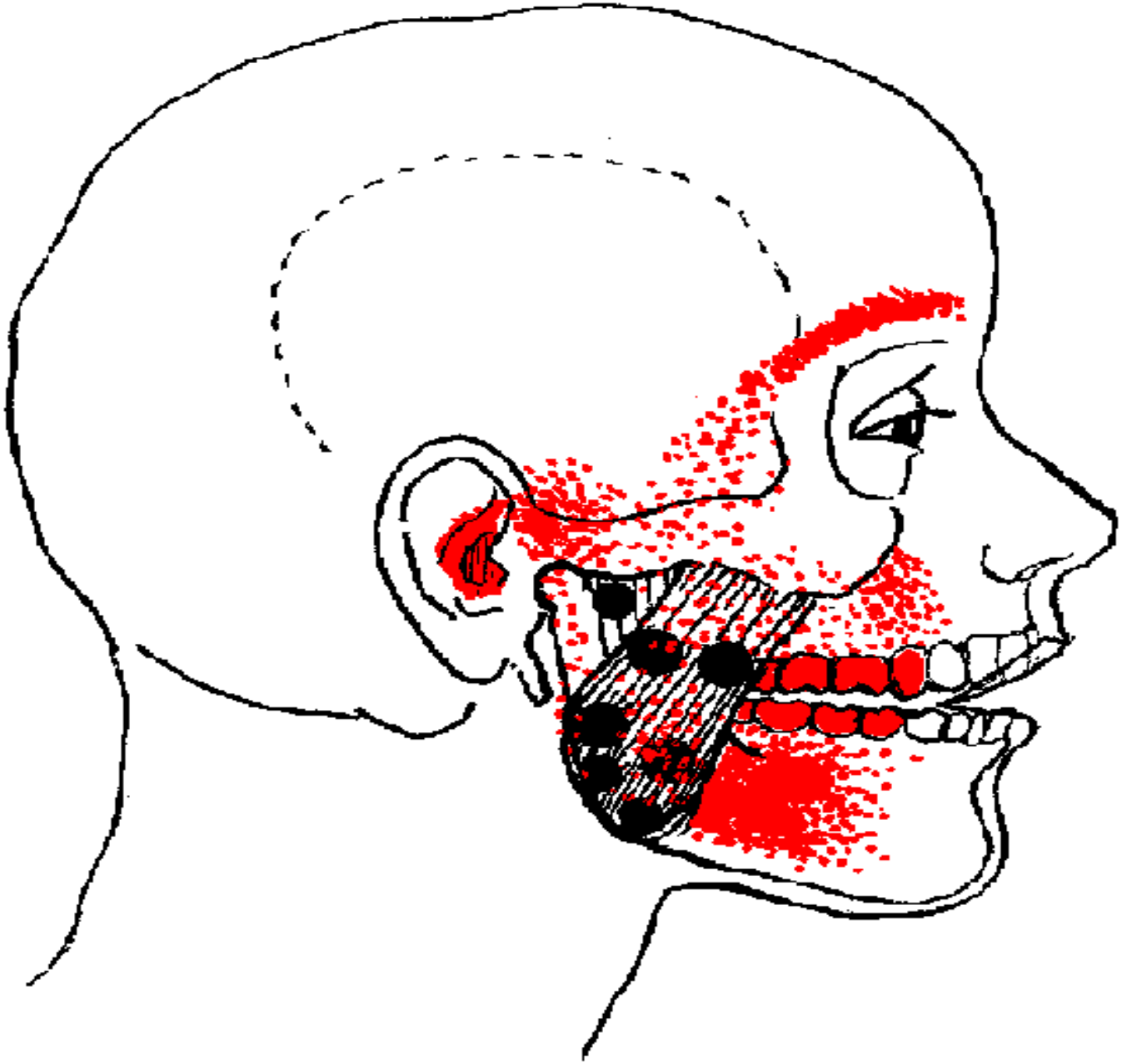

Source: http://round-earth.com/HeadPainIntro.html with permission to use by C.M. Shifflett

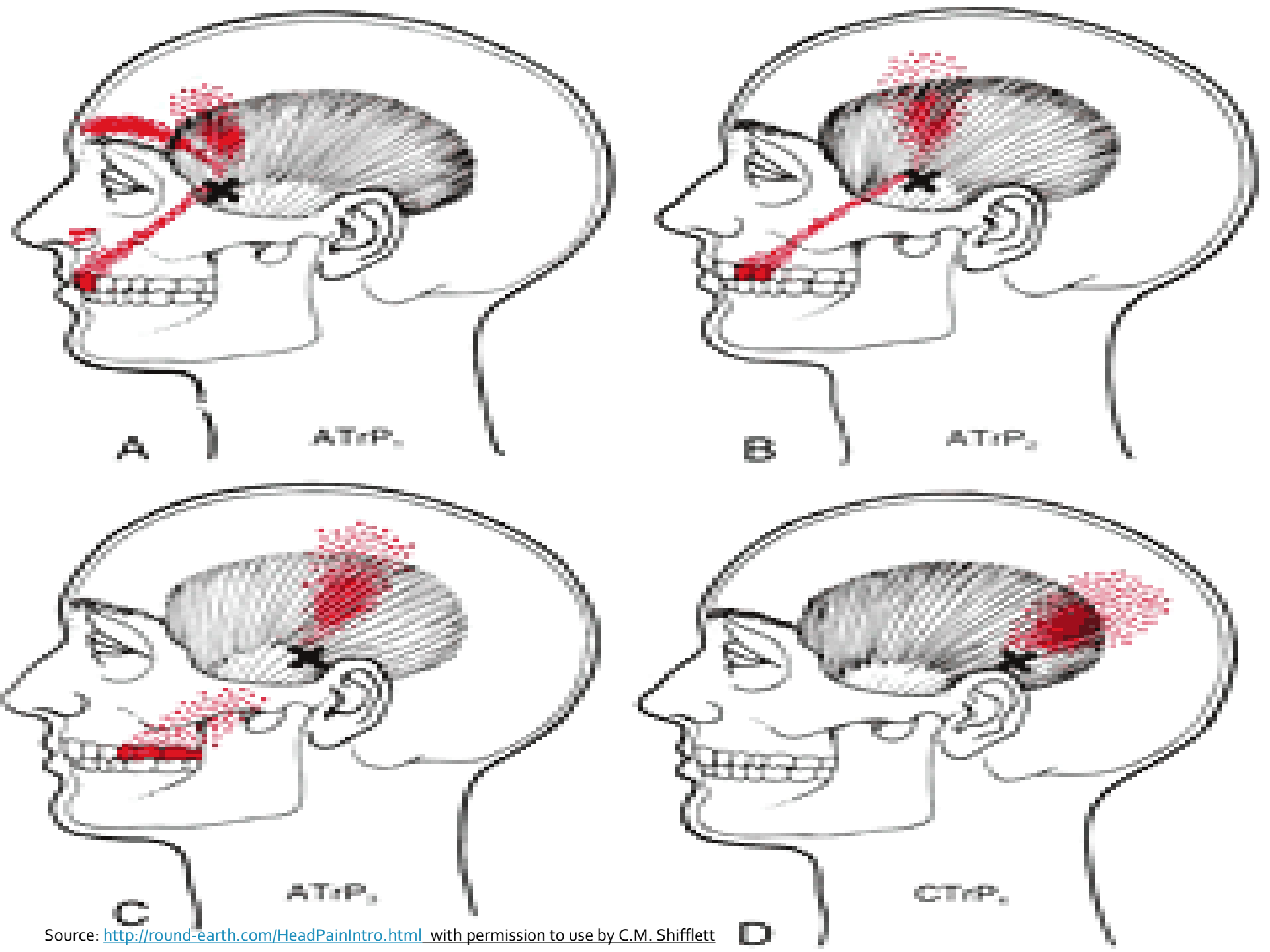


Source: http://round-earth.com/HeadPainIntro.html with permission to use by C.M. Shifflett

# CRANIOMANDIBULAR PTHA

- A frequently overlooked cause of PTHA.
- Clicking, popping or malocclusion of the joint may occur.
- Non-traumatic causes are common:
  - stress
  - dental malocclusion
  - prior psychosexual abuse

http://www.urmc.rochester.edu/imaging/patients/procedures/tmj-imaging.aspx

# NEUROMA & NEURALGIC HEADACHE

- Neuritic scalp pain may occur from local blunt trauma, surgical scalp incision or penetrating scalp injuries.
- Occasionally, neuromatous lesions may form after scalp nerve injury and serve as a pain nidus.
- Pain complaints may vary from only reports of dysesthetic “numbness” discomfort on touching to lacinating type pain that spontaneously occurs without provocative measures.

# NEUROMA & NEURALGIC HEADACHE

- Occipital nerve pain is typically felt at the craniocervical junction and the sensory distribution of the nerve (e.g. C2).
- The affected nerve is tender to palpation.
- Palpation generally replicates the pain associated with the headache (e.g. stabbing quality).
- There is frequently referral of pain into the ipsilateral frontotemporal scalp and less frequently retro-orbitally.

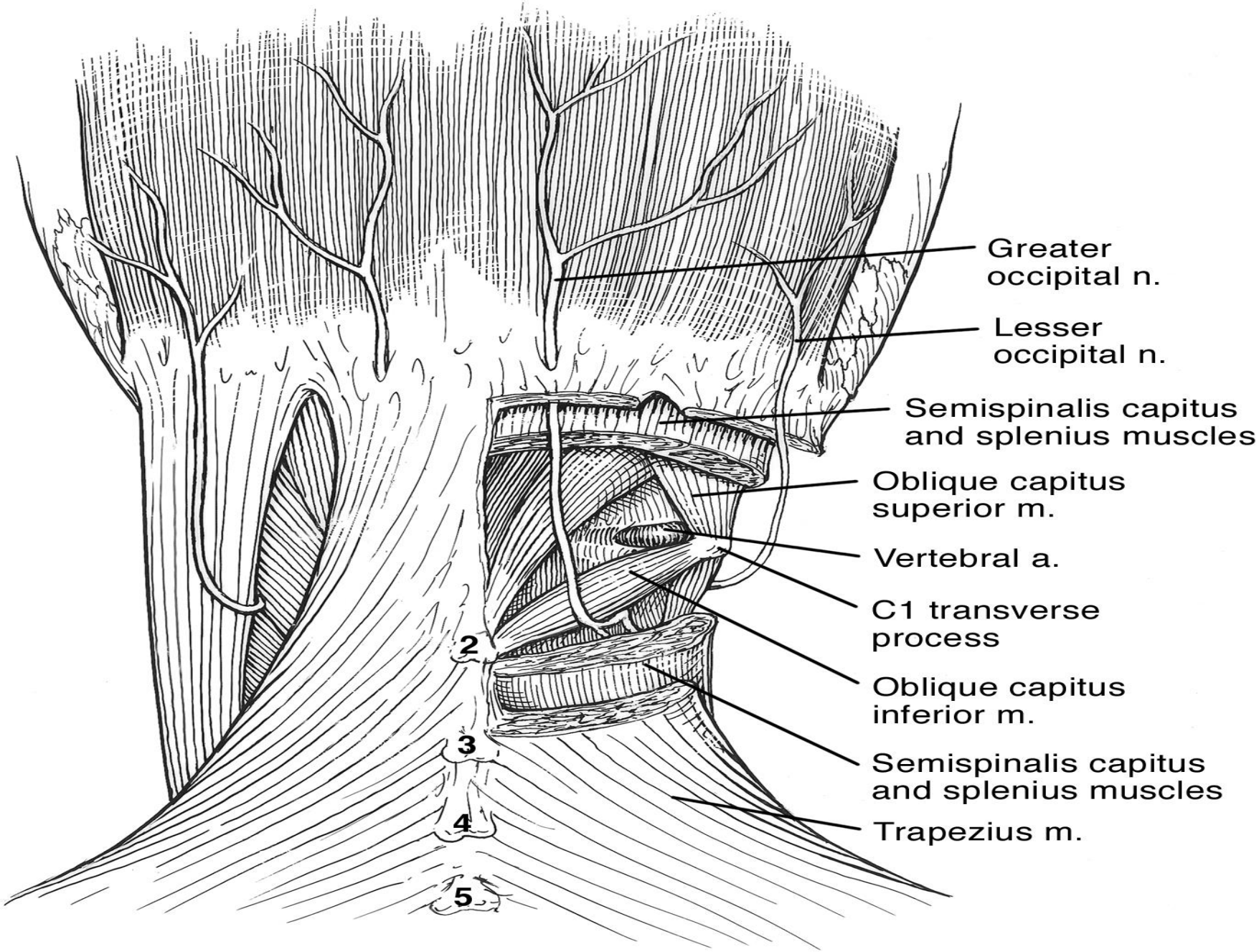


Source: Brain Injury Medicine, 2013

# BLOCKING CNV BRANCHES

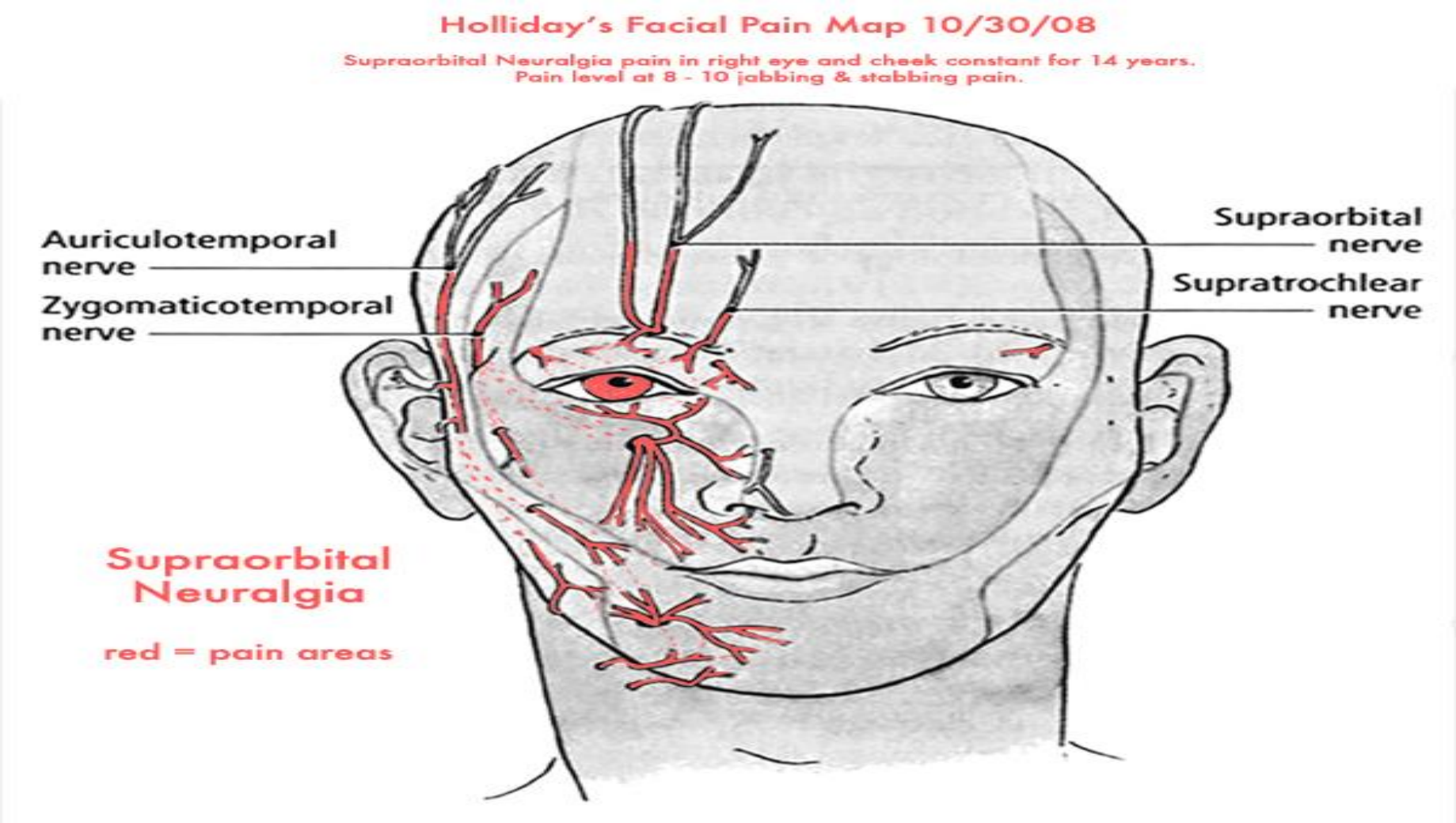


Source: Brain Injury Medicine, 2013

# NEUROMA AND NEURALGIC HEADACHE

- For greater occipital nerve or lesser occipital nerve in particular, clinicians should be familiar with the anatomy of the region given risks of vascular trauma with aberrantly placed injections.
- In either situation, myofascial pain may be a secondary or perpetuating pain generator and must be treated as well (typically first).

# MIGRAINE HEADACHE

- **Possible findings during a migraine include the following:**
- Cranial/cervical muscle tenderness
- Horner syndrome (relative miosis with 1-2 mm of ptosis on the same side as the headache)
- Conjunctival injection
- Tachycardia/bradycardia

# MIGRAINE HEADACHE

- Hypertension/hypotension
- Hemisensory or hemiparetic neurologic deficits (implies complicated migraine)
- Adie-type pupil (poor light reactivity, with near dissociation to light)
- **Look for nociceptive afferent pain generators**

# TENSION HEADACHE

- **Findings in TTHA:**
- Normal neurologic examination
- Tenderness may be elicited in the scalp or neck, but no other positive physical exam findings should be noted.
- Pain should not be elicited over temporal arteries or positive trigger zones.

# TENSION HEADACHE

- Some patients with occipital tension headaches may be very tender when upper cervical muscles are palpated.
- Pain associated with neck flexion and stretching of paracervical muscles must be distinguished from nuchal rigidity associated with meningeal irritation.
- **Look for nociceptive afferent pain generators**

# CONCLUSIONS

- Understanding how to take a PTHA history can significantly improve the clinician's odds of honing in on the specific pain generators involved in headache production.
- Understanding the complexities of the PTHA physical exam are crucial to confirmation of headache pain generators and to guiding appropriate PTHA treatment.
- Strong PTHA headache assessment skills are crucial to optimizing patient  clinical outcomes.

Photo Credit: veer.com

# QUESTIONS AND ANSWERS

# Thank You

NATHAN ZASLER, MD
NZASLER@CCCV-LTD.COM